

ANGULAR OR TUBO-UTERINE PREGNANCY

(With A Report on Four Cases)

by

PREMA M. NAIDU*, M.D., F.R.C.S.E., F.R.C.O.G.

MALATHI S. JATKER**, M.B.B.S., D.G.O.

and

K. KANAKADURGAMBA***, M.D., M.R.C.O.G.

Although Solomons had referred to interstitial pregnancy as being synonymous with cornual pregnancy, these two conditions should be appreciated as separate anatomical and clinical entities. Cornual pregnancy occurs in one horn of a bicornuate uterus. If implantation takes place in the intra-mural part of the fallopian tube it is known as interstitial pregnancy. Hence, when distension of any one cornu of the uterus is met with, it may be produced not only by cornual but also by interstitial pregnancy or one of its sub-varieties. Several classifications based on the site of implantation have been formulated according to whether the ovum occupies the outer, middle or inner third (the tubo-uterine segment) of the interstitial part of the tube. And the termination is also influenced by the location of the original embedding. In the tubo-uterine or the angular preg-

nancy, so called by Munro Kerr, the ovum may completely abort into the uterine cavity, grow partly into it or may occasionally develop into maturity. An angular pregnancy is also known to rupture into the peritoneal cavity as reported by Riddel and Scholefield.

Some interesting aspects of angular pregnancy have been presented severally by Johnston and Moir, Fitzgerald, McDonald, McNeil and others. The differential diagnosis of a pregnant uterus with distortion at one cornu, if it is at all possible, would prove helpful since it might occasionally end in an abdominal catastrophe.

Four further cases of angular pregnancy were met with recently at the Government Maternity Hospital, Hyderabad. The first two cases were admitted with intra-peritoneal rupture and collapse. The third is reviewed in order to illustrate how a pregnancy might actually occur in the residual angle of an uterus which has been previously subjected to fundectomy. The last woman who turned up during the preparation of this paper presented an extreme example of an angular pregnancy going

* Professor of Obstetrics and Gynaecology.

** Junior Pathologist.

*** Professor of Clinical Obstetrics
Institute of Obstetrics and Gynaecology,
Government Maternity Hospital, Hyderabad—India.

to term and delivering the infant herself from below.

Case Reports

Case 1. K. B. (12096), age 25 years, para 6, was admitted on 17th September, 1959, complaining of severe pain on the right side of the lower abdomen for about 2 hours prior to admission. Five days earlier she had experienced, while in bed, an intermittent type of severe pain. There was also a history of amenorrhoea for 9 weeks, followed by a fair amount of vaginal bleeding which had occurred at the onset of pain. On admission she was pale, her pulse rate was 100 per minute, and her blood pressure 100/80 mm. Hg. On vaginal examination, the uterus was found to be enlarged to a size of 8 weeks' gestation and tender. A diagnosis of disturbed tubal pregnancy was made and an immediate laparotomy was decided upon. As soon as the abdomen was opened, the body of the uterus was sought for, and pulled up in order to identify and clamp presumably the ruptured right tube. The tubes and ovaries were found to be normal while the uterus itself appeared to be the seat of pregnancy and rupture. Both the round ligaments and the uterine ends of the fallopian tubes presented normal relations to each other on both the sides. But the uterus at its right horn, superior to the insertions of both the tubes and round ligaments presented a conical enlargement (Fig. 1, a). The surface of this swelling was dusky and covered with dilated blood vessels. At its summit there was a rent 3 cms. x 2 cms. wide, situated 1 cm. behind (Fig. 1, b) and above the insertion of the right tube. Through this, two finger-like processes of placental tissue, each 2 cms. long, were found to be extruding into the peritoneal cavity (Fig. 1, c & d). A small amniotic sac could be seen shining through the rent. The peritoneal cavity contained a large amount of fluid blood and clots. The diagnosis of a ruptured angular pregnancy was apparent. Since the patient had three living children, a total hysterectomy along with removal of right tube and ovary was carried out. Patient made an uneventful recovery. Several sections of the tube in its interstitial portion showed no tropho-

blast tissue nor any external evidence of congenital malformation was apparent.

Case 2. B. (12508-K.E.M.), age 24 years, nullipara, was admitted on 22nd September, 1959, with a history of 4 months' amenorrhoea and severe pain in the left iliac fossa of 6 hours' duration. Her previous menstrual history was normal. On admission she was in a state of shock with a pulse rate of 130 per minute and blood pressure of 75/50 mm. Hg. There was a generalised tenderness all over the abdomen. Bimanually the uterus was found enlarged to half way up to the umbilicus, and left fornix was markedly tender and full. A ruptured tubal pregnancy was diagnosed. On opening the abdomen, an amniotic sac with a foetus and a portion of a well-formed placenta were seen floating in the midst of a large amount of free blood. The uterus was then found enlarged to a size of 14 weeks' gestation and the left cornu was enormously distended particularly above the attachment of the round ligament. A large rupture, 3 cms. x 4 cms. in size, was noted on the postero-superior aspect of this enlargement. In other words, the left angle appeared to have been literally blasted away. Through this opening a finger could be passed into the uterine cavity to a depth of 3-4 cms. (Fig. 2 a & b). The left tube and ovary were normal. The right tube, ovary and round ligament were also noted in normal relationship to each other. As the patient was a nullipara, it seemed essential to be conservative. A clamp was applied on to the tube, ovarian ligament and broad ligament vertically on the left side and another was placed obliquely across the cornu of the uterus. The cornu was thus excised. A few stray villi seen in the opening were removed and the opening in the uterine cavity was then sutured in layers with 2/0 chromic catgut. The abdomen was closed. The patient made an uneventful recovery. A hystero-gram done 6 weeks' later did not reveal any congenital malformation of the uterus.

Case 3. W. B. (1092), age 30 years, para 1, was admitted on 19th February, 1960, with a history of 2 months' amenorrhoea and slight vaginal bleeding on and off for one month. She had had a fundectomy done for adenomyosis 3 years previously and

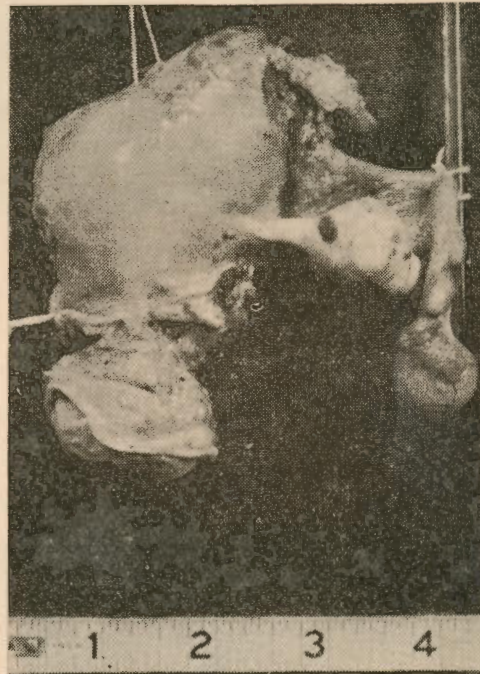
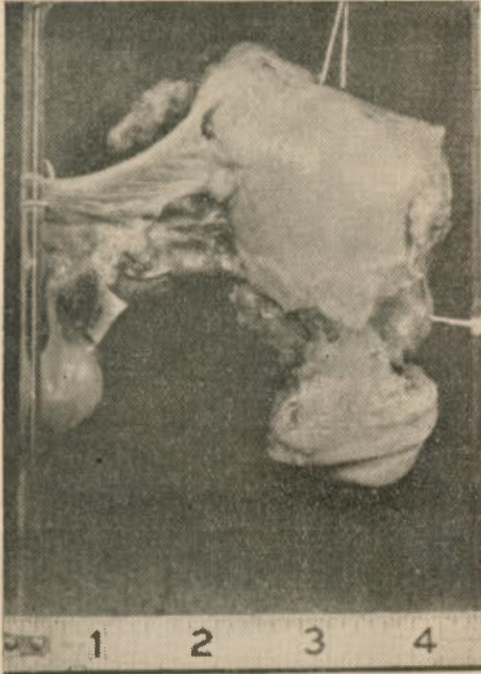
was delivered of a live child by a lower segment caesarean section a year later. On admission her general condition was good. Abdominal palpation revealed nothing abnormal. On bimanual examination, the right side of the residual uterus was found distended to the size of a duck's egg. The os was closed and there was brownish red discharge on the examining finger. Early pregnancy with threatened abortion was suspected. As she continued to have colicky pain and vaginal discharge, an evacuation of the uterine contents was decided upon. The uterine sound could be directed only towards the right side. And as it could easily be palpated through the abdominal wall, a perforation of the uterine wall was suspected and an immediate laparotomy was organised. On opening the abdomen, the "uterus" was found to be distended on the right side of the previous fundectomy scar. This was tense and cystic. The surface was injected. The infundibulo-pelvic ligament on the right side was varicose. Both the right and the left tubes could be identified in their entire length, though found covered with filmy adhesions. The pelvic colon was found to be adherent to the posterior wall of the uterus at the site of the previous scar caused by fundectomy. In order to conserve her menstrual function, an effort was made to remove only the pregnant part of the uterus. The cut surface showed a narrow channel of communication (Fig. 3, a) about 1/2 cm. in diameter between the pregnant and non-pregnant parts. Note thinning of sac wall and its contents in Fig. 3, b. During excision, the knife was felt passing through hard fibrous tissue, which showed bluish spots suggestive of recurrent adenomyosis. The right round ligament was restored to the remaining cornu of the "uterus" after making an effort to bring into apposition its anterior and posterior walls by interrupted catgut sutures. Although the patient stood the operation well, she had a stormy convalescence requiring another laparotomy 2 weeks later for intestinal obstruction from which complication also she recovered. The presence of products of conception was verified on microscopic section. Fig. 4 indicates the alterations in the uterine contour at the two operations.

Case 4. K. A. (3392), age 35 years, para 2, was admitted on midnight of 10th March, 1961, for retained placenta 10 hours after she had spontaneously delivered at home, a live male infant weighing 6½ pounds. A manual removal had been attempted in vain by a midwife before admission. She has had two previous pregnancies ending in normal deliveries at term. The present pregnancy which had also been uneventful, though she had had no antenatal care, had ended in an easy delivery. There had been no postpartum bleeding. But, she on admission appeared dehydrated and toxic with a pulse rate of 120 per minute and the temperature was 102° while the blood pressure was 100/70 mm. Hg. The lower abdomen was slightly distended and tender while the uterus could be palpated up to the umbilicus. Six inches of umbilical cord was found hanging from the vulva. When an attempt was made to remove the placenta, the cervical canal admitted only two fingers and no placenta could be palpated within reach. Her blood showed 3 million red cells and 8 gms. of haemoglobin. A partial rupture of the uterus was suspected and she was put on intravenous Terramycin and intramuscular Hydrocortisone. During the next 24 hours, while on antibiotic and supportive therapy, she developed paralytic ileus. By then a hysterectomy was deemed inevitable as soon as the ileus could be controlled. On the 14th of March, when the abdomen was opened, 2-3 ounces of offensive yellowish fluid was noted amidst a few plastic adhesions that were present between the bowels and the pelvic organs. The uterine contour was noted to be normal except for a pear-shaped dusky enlargement at the right cornu. The wall of this swelling was thin and contained what looked like the full-term placenta with some organised blood clots. While separating the adhesions from the top of the mass, the sac wall gave way, and it led to some brisk bleeding. A total hysterectomy was carried out as blood was being transfused. After 48 hours of stormy convalescence her condition began to improve. The patient and her infant were discharged well on the 14th day.

Figure 5 shows the uterine cavity with the 'cord' after the delivery of the foetus and the right cornu distended with the placenta.

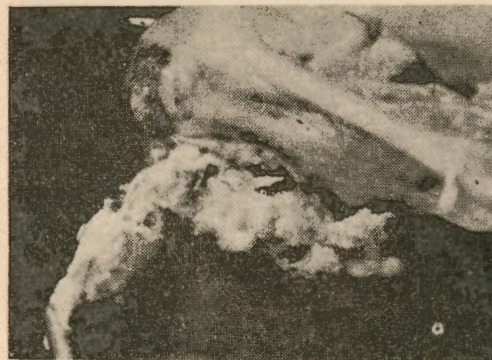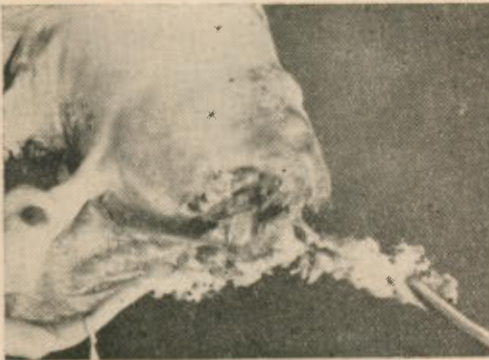
Most of the right tube could be easily identified. The round ligament is attached below the junction of the cornual enlargement to the main uterus. The uterine wall was found to be hypertrophied as that of any puerperal uterus, but the cavity was covered with a smooth decidual lining. The course of events in this case and the specimen point to the possibility of the implan-

tation of the ovum at the right angle of the uterus (tubo-uterine segment of the interstitial part) with the escape of the foetus into the uterine cavity with its amniotic sac, at some early stage of pregnancy. The foetus in this case had continued to develop to its full maturity and had been delivered by the uterus exactly as in a normal intra-uterine gestation.



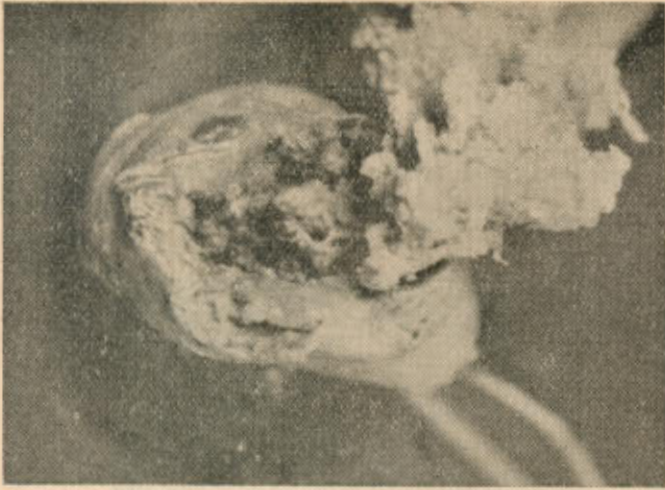
Case 1, Fig. 1(a)—Anterior view. Angular pregnancy.

Case 1, Fig. 1(b)—Posterior view. Angular Pregnancy showing rupture.

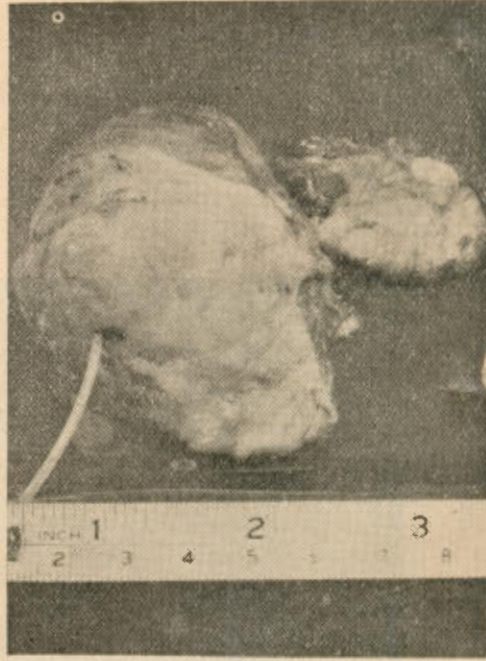


Case 1, Fig. 1(c)—Close up view of (b).

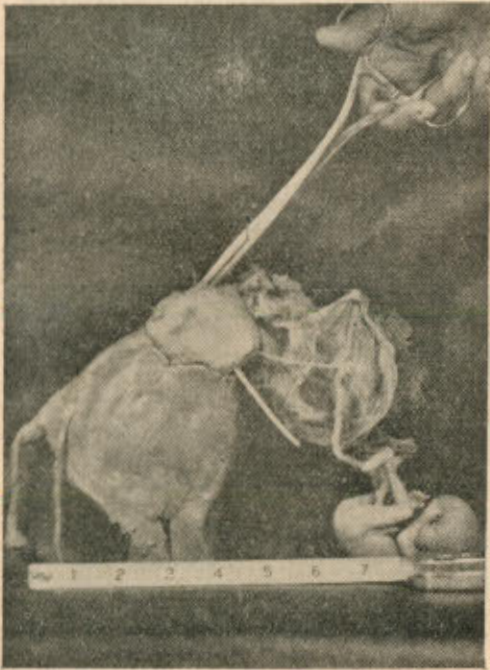
Case 1, Fig. 1(d)—Close-up lateral view.



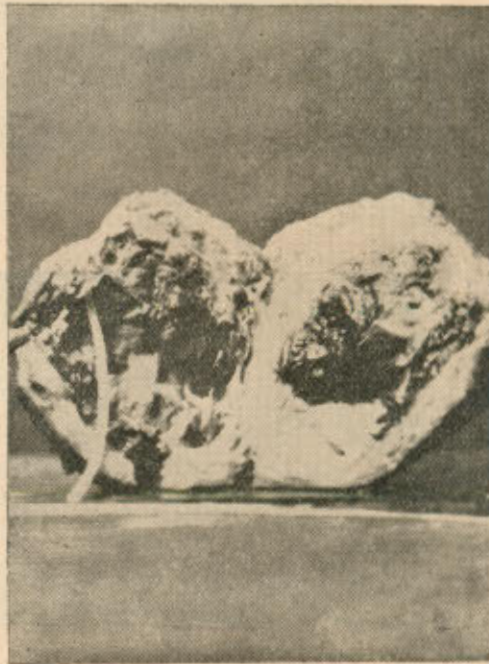
Case 2, Fig. 2(a)—Excised cornu showing a large rupture.



Case 3, Fig. 3(a)—Appearance of the excised cornu. The recurrent adenomyosis on the coronal septum and the narrow channel of communication.



Case 2, Fig. 2(b)—Anterior view of the uterus as reconstructed.



Case 3, Fig. 3(b)—Sac wall thinned out and distended with products of conception.

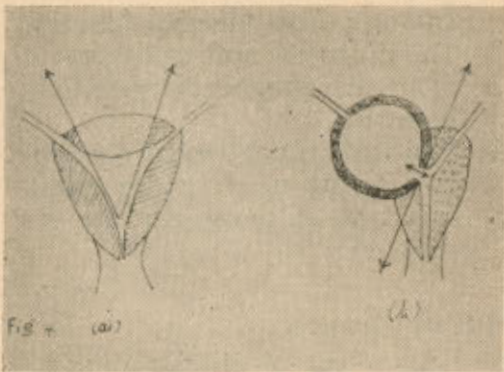


Fig. 4(a)—The uterus at fundectomy. Fig. 4(b)—The residual uterus at cornuectomy.

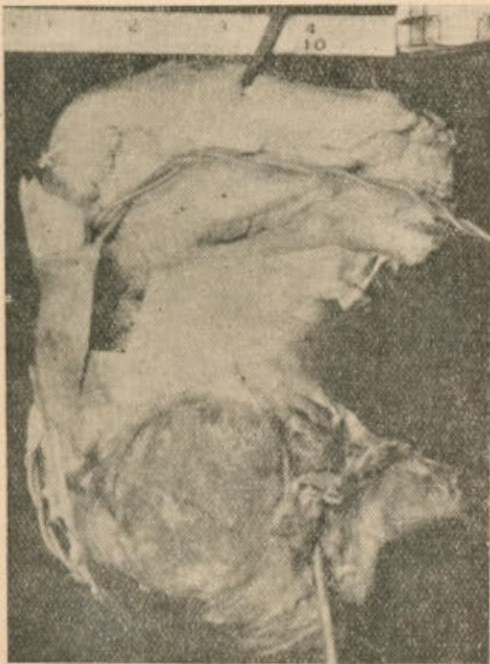


Fig. 5—The specimen of tubo-uterine (angular) pregnancy after the spontaneous delivery of the fetus.

Discussion

Pregnancy in the angle of the uterus (Munro Kerr) embedding in the utero-interstitial moiety of the fallopian tube (Klebs—quoted by

Hyams) or nidation at the funnel of the tube (Lisa *et al*) are some of the diverse anatomical terms used in describing what Fitzgerald aptly calls the obscure "corner of obstetrics."

Although an angular pregnancy may get itself rectified into normal uterine pregnancy, it might give rise to difficulty in diagnosis in the early weeks due to the initial one-sided enlargement of the uterus. But it is generally held that the abnormal shape of the uterus might disappear sooner or later. A hysteroqram after delivery would usually set right any mistake as pointed out by the French authors, Granjou and Beau (quoted by Fitzgerald).

In Johnston and Moir's case of angular pregnancy a partial extrusion of the gestation sac into the uterine cavity had occurred besides causing a distension of the uterine wall and rupture into the peritoneal cavity. A rupture occurring into the peritoneal cavity would necessarily simulate a ruptured tubal pregnancy as noted in Cases 1 and 2 reported here. A more accurate pre-operative diagnosis of the uterine involvement could perhaps have been made in the first case, if due attention had been paid to the profuse vaginal bleeding associated with the undue tenderness of the uterus.

That an implantation of an ovum at the angle of the uterus is not only possible but that it might continue to grow for a variable period causing unilateral distortion of the uterus is demonstrated by Case 3. The funnel had apparently dilated leading to distension of the uterine orifice of the tube and thinning of the uterine wall. The adjustment that had occurred during the first pregnancy following

fundectomy had failed to occur this time because the cornual scar had developed into an unyielding septum on account of recurrent adenomyosis. In the fourth case, which is a good example of this abnormal nidation, the pregnancy had not only reached maturity but spontaneous vaginal delivery had been accomplished.

As regards treatment of a case of angular pregnancy, a hysterectomy may be indicated as in Case 1. And even in Case 2, a more radical step than cornuectomy might have been safer but for the urge to retain her reproductive ability. Case 3, of course, created a peculiar problem in that the entire angle had to be resected along with the adnexa in an attempt to conserve the unaffected angle, though it was difficult to peritonise the raw surface, because of the coronal septum which was rigid with adenomyosis. Hysterectomy was the obvious treatment in Case 4.

Conclusions and Summary

1. The subject of cornual distension of the uterus with pregnancy is introduced with an over-simplified differentiation of the conditions causing it.
2. Two cases of angular pregnancy with rupture are reported. The third case is considered here to illustrate the possibility of an ovum being implanted at the residual angle of uterus. Finally, the fourth case depicts the extreme possibility of the pre-

gnancy reaching maturity and ending in spontaneous delivery.

3. The diagnosis and management of angular pregnancy are briefly indicated.
4. The various anatomical descriptive terms used in describing this type of pregnancy are recounted.

Acknowledgement

We thank Mr. J. V. Desai, M.B., F.R.C.S.E., of Gandhi Medical College, Secunderabad, for the excised cornu and the clinical notes of Case 2.

References

1. Fitzgerald T. B.: J. Obst. Gyn. Brit. Emp.; 59, 518, 1952.
2. Hyams M. N.: Am. J. Obst. & Gyn.; 65, 697, 1953.
3. Johnston L. W. and Chassar Moir J.: J. Obst. Gyn. Brit. Emp.; 59, 85, 1952.
4. Lisa *et al.*: Surg. Gyn. & Obst.; 99, 159, 1954.
5. McDonald I. A.: J. Obst. Gyn. Brit. Emp.; 64, 712, 1957.
6. McNeil A. T.: J. Obst. Gyn. Brit. Emp.; 64, 880, 1957.
7. Munro Kerr K. M.: "Operative Obstetrics" (ed. 6); London, Baillieres, Tindall and Cox, 1956.
8. Naidu *et al.*: J. Obst. Gyn. Brit. Emp.; 65, 994, 1958.
9. Riddel J. and Scholefield J.: Brit. M. J.; ii, 177, 1938.
10. Solomons B.: J. Obst. Gynec. Brit. Emp.; 56, 1045, 1949.